Lecture :1 .General description of the cells

Name of the instructor: Dr.Luma Yousif Mehdi

Cell Structure and Function

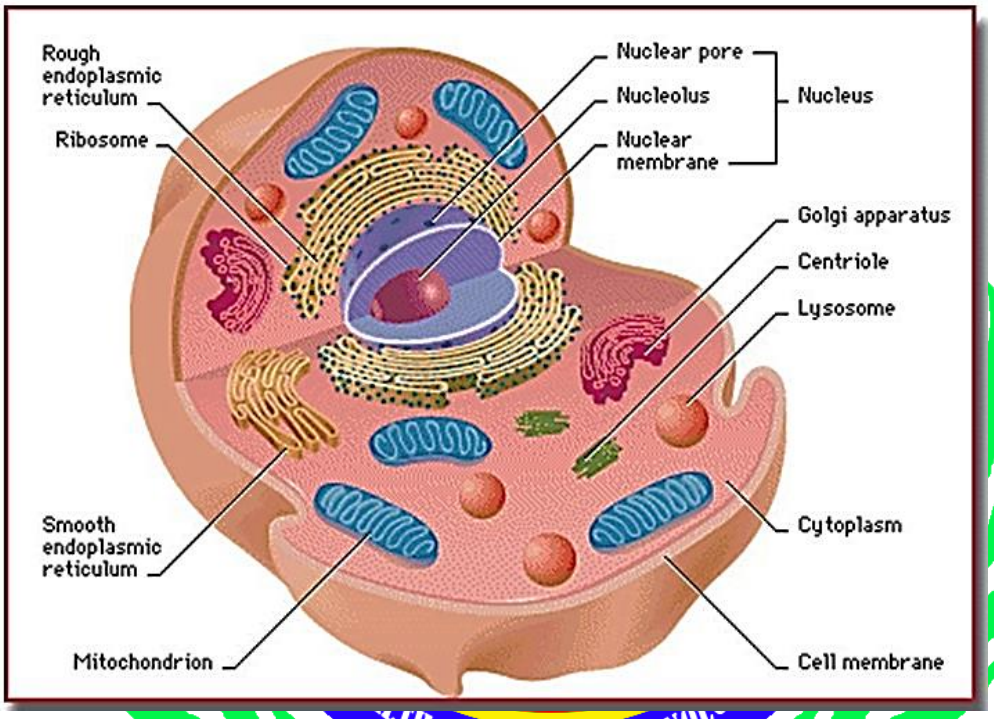

A cell is the basic unit of life. All living organisms are made up of cells.

Plasma Membrane : **The plasma membrane isolates the interior of the cell from the external environmentand is a selectively permeable membrane,made up of a double-layered sheet called a lipid bilayer .**

The Nucleus :**stores the genetic information as DNA organized into linear structurescalled chromosomes.** Located on the chromosome are collections of genes**. Genes are segments of DNA that contain information for the production of specific proteins.** These proteins have many functions in cells, and they help determine a cell's specificity.

Chromatin is the combination of DNA molecules and proteins that make up the chromosomes. The chromosomes are responsible for transmitting genetic information from one generation to the next. Chromatin can coil tightly to form visible chromosomes during cell division.

The nucleus is separated from the cytoplasm by a double membrane known as the nuclear envelope. This is continuous with the **endoplasmic reticulum (ER),** a membranous system of

---

saccules and channels**.**The nuclear envelope has nuclear pores of sufficient size to permit the passage of ribosomal subunits out of the nucleus and proteins into the nucleus.

Ribosomes are organelles composed of proteins and rRNA. Protein synthesis occurs at the ribosomes. Ribosomes are often attached to the endoplasmic reticulum, but they also may occur free within the cytoplasm, either singly or in groups called *polyribosomes.*

The **endoplasmic reticulum (ER)** has two portions. ***Rough ER* is studded with ribosomes on the side of the membrane thatfaces the cytoplasm. The proteins that are synthesized at these ribosomes enter the interior of the ER** for additional processing and modification.

The *smooth ER* is continuous with the rough ER, but it does not have attached ribosomes.

Smooth ER synthesizes the phospholipids and other lipids that occur in membranes. It also has various other functions, depending on the particular cell. For example, in the testes it produces testosterone, and it helps detoxify compounds (such as drugs) in the liver.

The ER forms transport vesicles in which large molecules are transported to other parts of the cell. Often these vesicles are on their way to the plasma membrane or the Golgi apparatus.

The Golgi apparatus consists of a stack of slightly curved saccules, . Here proteins and lipids received from the ER are modified. The vesicles that leave the Golgi apparatus move to other parts of the cell. Some vesicles proceed to the plasma membrane, where they discharge their contents. In all, **the Golgi apparatus is involved in processing, packaging, and secretion.**
Lysosomes, membranous sacs produced by the Golgi apparatus,contain enzymes.
Lysosomes are small organelles filled with enzymes. Lysosomes break down lipids, carbohydrates, and proteins into small molecules that can be used by the rest of the cell.
Centrioles are located near the nucleus and help organize cell division. Centrioles are not found in plant cells.
Mitochondria are often called the powerhouses of the cell, producing ATP molecular.

Lecture:2&3: Tissue definition & classification

A tissue is composed of specialized cells of the same type that perform a common function in the body. The tissues of the human body can be categorized into four major types:

- **Epithelial tissue covers body surfaces and lines body cavities.**
- **Connective tissuebinds and supports body parts.**
- **Muscular tissuemoves the body and its parts.**
- **Nervous tissuereceives sensory information and conducts nerve impulses.**
- **Epithelial Tissue Protects**

Epithelial tissue, also called *epithelium* (pl., epithelia), consists of tightly packed **cells that form a continuous layer,** covers surfaces and lines body cavities. it has a protective function. It can also be modified to carry out secretion, absorption, excretion, and filtration. Epithelial cells are named based on their appearance, **they are bounded by a basement membrane**(is a thin layerthat anchors the epithelium to underlying connective tissue).

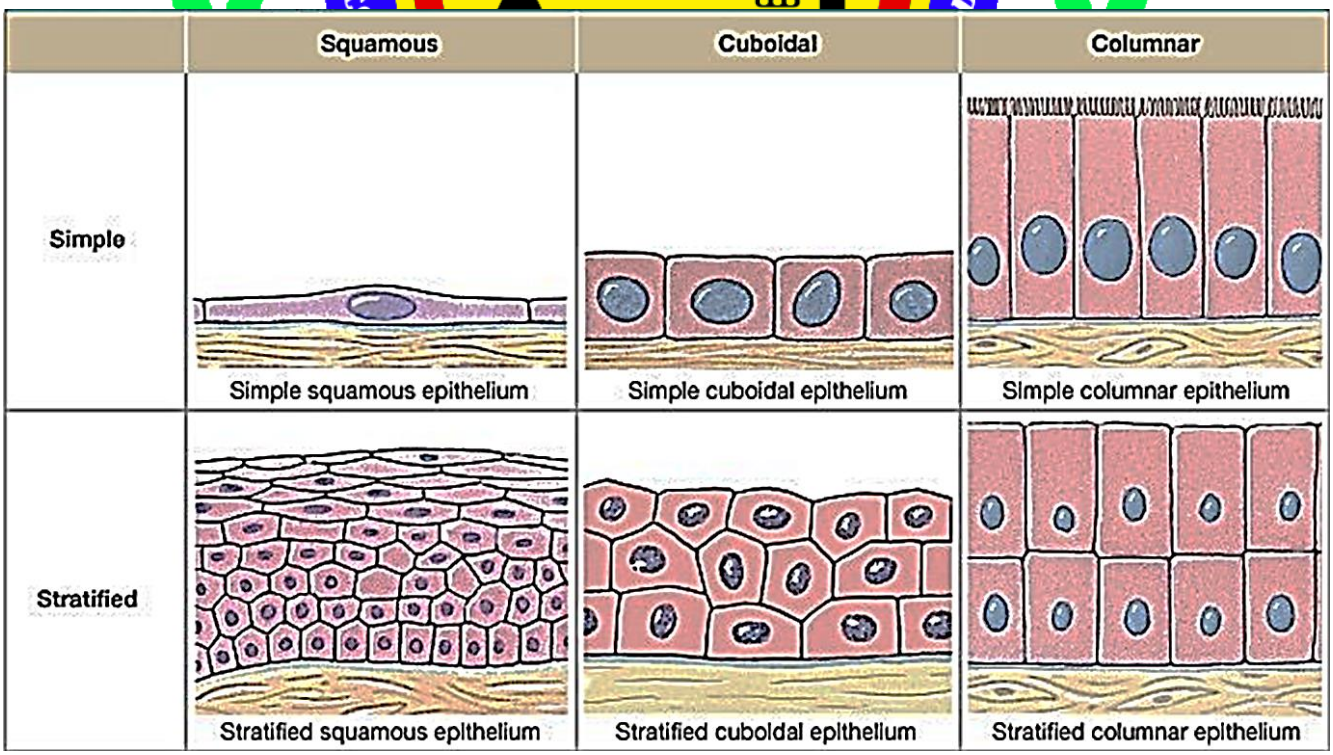

Figure : Classifying Epithelia

✓ **Simple Epithelia**

Epithelial tissue is either simple or stratified. Simple epithelia have only a single layer of cells and are classified according to cell type**. Squamous epithelium, composed of flattened cells**, is found lining the air sacs of lungs and walls of blood vessels.

Cuboidal epithelium consists of a single layer of cube-shaped cells. This type of epithelium is frequently found in glands, such as the salivary glands, the thyroid, and the pancreas**.** Simple cuboidal epithelium also covers the ovaries and lines kidney tubules, the portions of the kidney in which urine is formed.

Columnar epithelium has cells resembling columns, with nuclei usually located near the bottom of each cell. This epithelium lines the digestive tract, where microvilli expand the surface area and aid in absorbing the products ofdigestion.

A gland can be a single epithelial cell, as in the case of the mucus-secreting goblet cell, or a gland can contain many cells. Glands with ducts that secrete their product onto the outer surface(e.g., sweat glands and mammary glands) or into a cavity (e.g., salivary glands) are called exocrine glands. Ducts can be simple or compound:

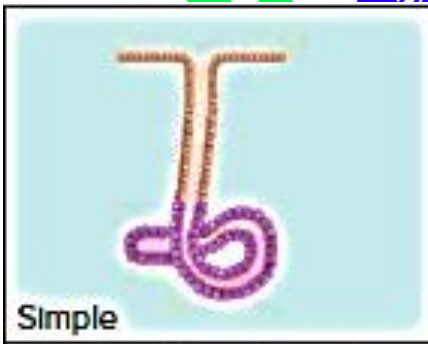	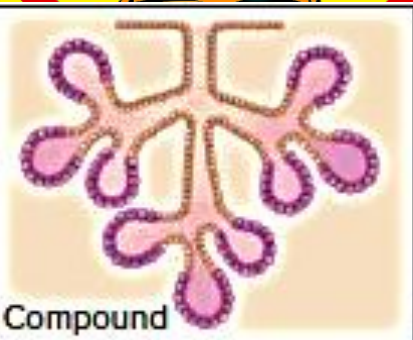	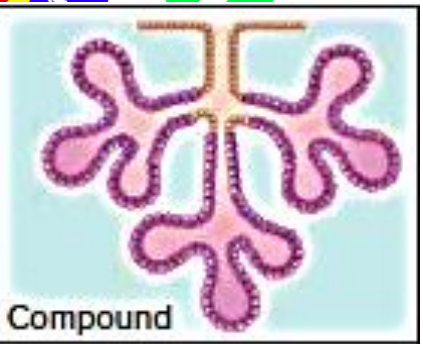
Simple	Compound	Compound
Example: Sweat gland	Example: Mammary gland	Example: Pancreas

Glands that have no ducts are known as the ductless glands, or endocrine glands. (e.g., pituitary and thyroid), which secrete hormones directly into the bloodstream,

---

Figure 3-23B. Sweat gland of the skin. H&E, ×377

Figure ,Unicellular gland, in small intestine

(a) Simple squamous epithelium

Description: Single layer of flattened cells with disc-shaped central nuclei and sparse cytoplasm; the simplest of the epithelia.

Function: Allows passage of materials by diffusion and filtration in sites where protection is not important; secretes lubricating substances in serosae.

Location: Kidney glomeruli; air sacs of lungs; lining of heart, blood vessels, and lymphatic vessels; lining of ventral body cavity (serosae).

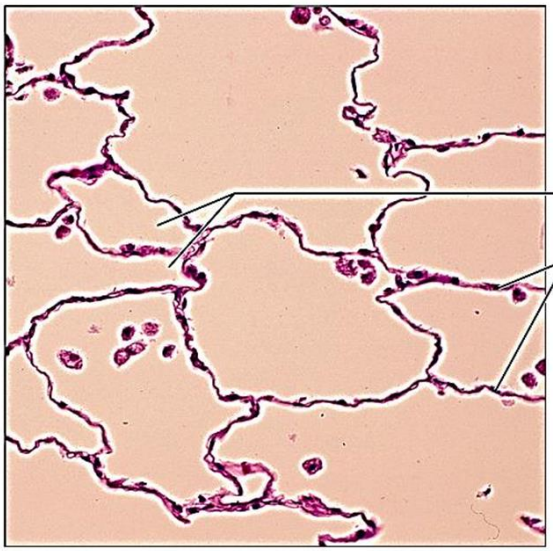

Photomicrograph: Simple squamous epithelium forming part of the alveolar (air sac) walls (400×).

(b) Simple cuboidal epithelium

Description: Single layer of cubelike cells with large, spherical central nuclei.

Function: Secretion and absorption.

Location: Kidney tubules; ducts and secretory portions of small glands; ovary surface.

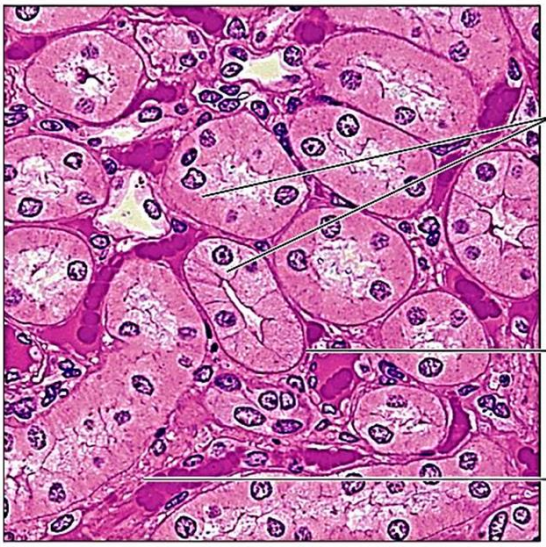

Photomicrograph: Simple cuboidal epithelium in kidney tubules (400×).

(c) Simple columnar epithelium

Description: Single layer of tall cells with *round* to *oval* nuclei; some cells bear cilia; layer may contain mucus-secreting unicellular glands (goblet cells).

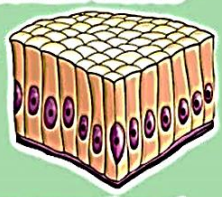

Function: Absorption; secretion of mucus, enzymes, and other substances; ciliated type propels mucus (or reproductive cells) by ciliary action.

Location: Nonciliated type lines most of the digestive tract (stomach to anal canal), gallbladder, and excretory ducts of some glands; ciliated variety lines small bronchi, uterine tubes, and some regions of the uterus.

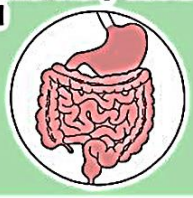

Photomicrograph: Simple columnar epithelium of the stomach mucosa (1300×).

Pseudostratified columnar epithelium is so named because it appears to be layered (*pseudo*, "false"; *stratified,"layers"*). it does not have true layers, because each cell touches the basement membrane, the irregular placement of the nuclei. The lining of the trachea pseudostratified ciliated columnar epithelium.

PSEUDOSTRATIFIED CILIATED COLUMNAR EPITHELIUM

LOCATIONS: Lining of nasal cavity, trachea, and bronchi; portions of male reproductive tract

FUNCTIONS: Protection, secretion

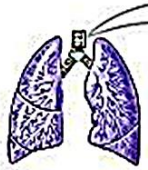

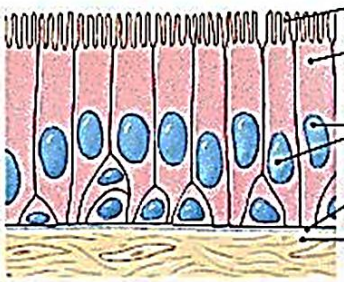

(b) Trachea

LM × 290

- ✓ **Stratified Epithelia**

Stratified epithelia have layers of cells . Only the bottom layer touches the basement membrane. (the nose, mouth, esophagus, anal canal **), the outer layer of skin is also stratified squamous epithelium, but the cells are reinforced by keratin, a protein that provides strength. Stratified cuboidal and stratified columnar epithelia also are found in the body.**

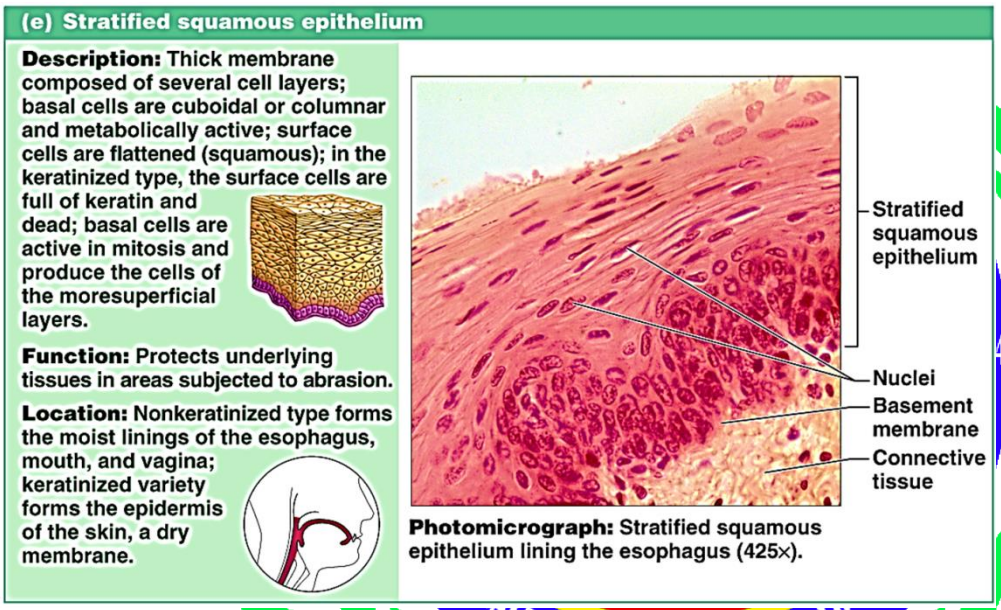

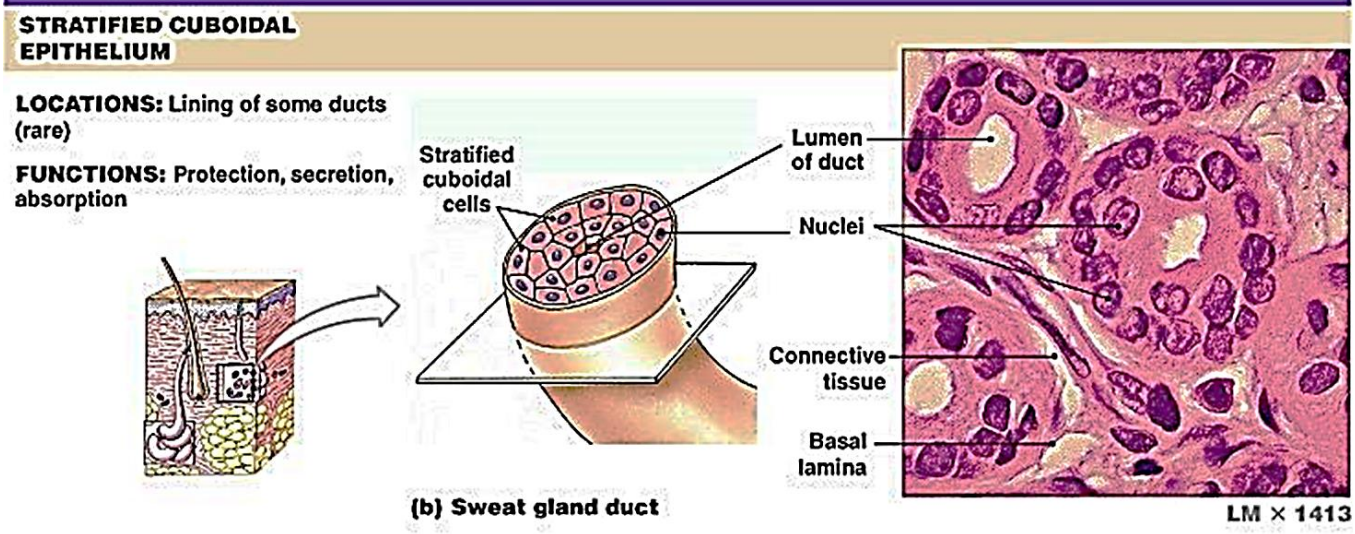

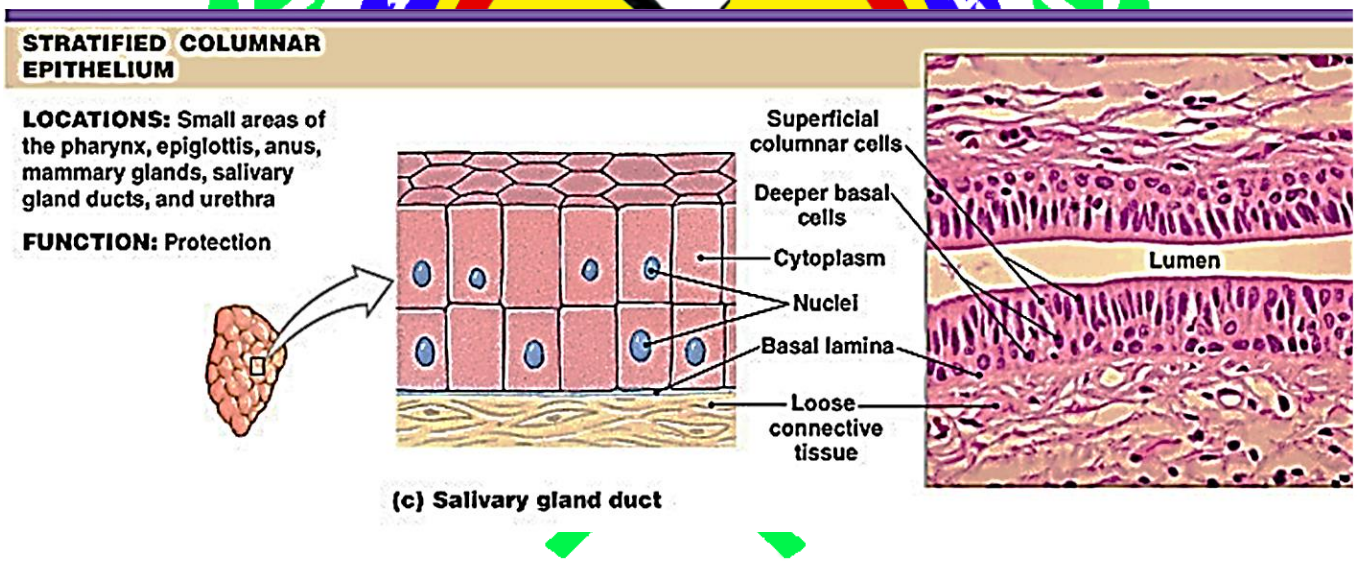

Transitional epithelium was originallytissue changes in response to tension. It forms the lining of the urinary bladder, the ureters (the tubes that carry urine from the kidneys to the bladder), and part of the urethra (the single tube that carries urine to the outside). All are organs that may need to stretch

(f) Transitional epithelium

Description: Resembles both stratified squamous and stratified cuboidal; basal cells cuboidal or columnar; surface cells dome shaped or squamouslike, depending on degree of organ stretch.

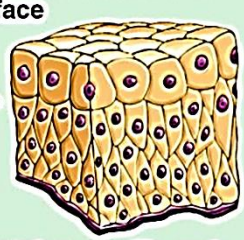

Function: Stretches readily and permits distension of urinary organ by contained urine.

Location: Lines the ureters, bladder, and part of the urethra.

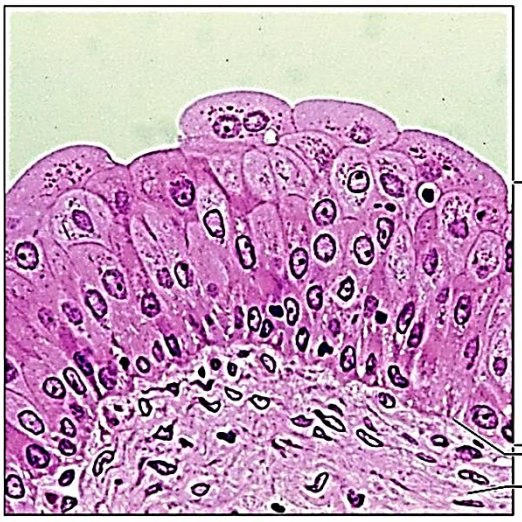

Photomicrograph: Transitional epithelium lining the bladder, relaxed state (500×); note the bulbous, or rounded, appearance of the cells at the surface; these cells flatten and become elongated when the bladder is filled with urine.

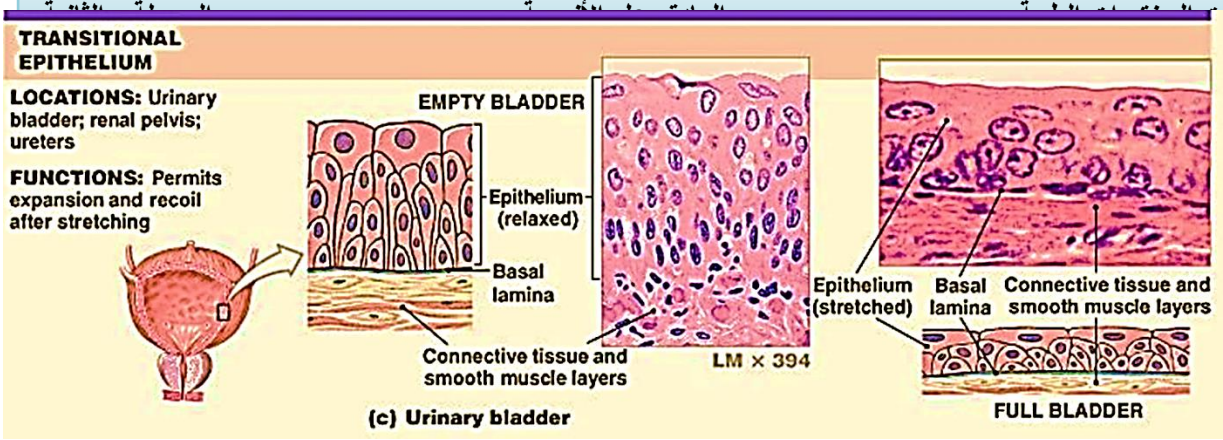

❖ **Lecture 3&4&5: Connective Tissue : Connects and Supports**

Connective tissue is diverse in structure and function. Despite these apparent differences**, all types of connective tissue have three similar components: specialized cells, ground substance, and protein fibers.** These components are shown in figure : a diagrammatic representation of loose fibrous

connective tissue. The ground substance is a non-cellular material that separates the cells. It varies in consistency from solid (bone) to semifluid (cartilage) to fluid(blood).

The fibers are of three possible types. White collagen fibers contain collagen, a protein that gives them flexibility and strength. Reticular fibers are **very thin collagen fibers**, **highly branched**

proteins that form delicate supporting networks. **Yellowelastic fibers contain elastin, a protein that is not as strong as collagen but is more elastic.**

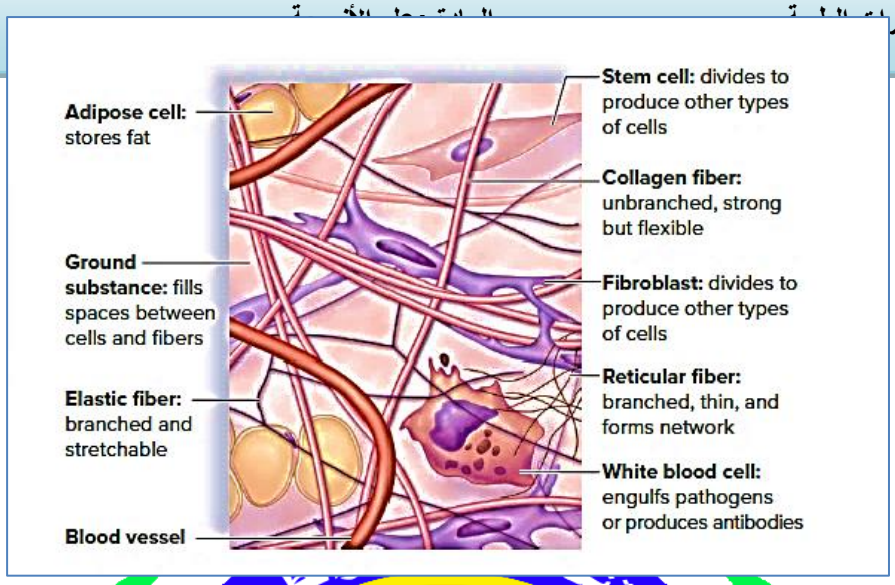

Figure :Components of connective tissues. All connective tissues have three components: specialized cells, ground substance, and protein fibers. Loose fibrousconnective tissue.

- ✓ Types of Connective Tissue:
- **CONNECTIVE TISSUE PROPER:**

Tissue exists **in two forms: loose fibrous tissue** and **dense fibrous tissue.** Both loose fibrous and dense fibrous connective tissueshave cells called fibroblasts located some distance from one another and separated by a jellylike ground substance containing white collagen fibers and yellow elastic fibers , Matrix includes ground substance and fibers.

Loose fibrous connective tissue, which includes areolar connective tissue**(**ex: below the epithelium in the lamina propria of the small intestine)**(more cells and fewer fibers) compared to dense connective tissue.Supports epithelium and many internal organs. Its presence in lungs, arteries,**

and the urinary bladder allows these organs to expand. **It forms a protective covering** enclosing many internal organs, such as muscles, blood vessels, and nerves.

Adipose tissue is a special type of loose connective tissue in which the cells enlarge and store fat.

Adipose tissue has little extracellular matrix. Its cells, which are **called adipocytes,** are crowded, and each is filled with liquid fat.The body uses this stored fat for energy, insulation, and organ protection.

Adipose tissue is primarily found beneath the skin, around the kidneys, and on the surface of the heart.

Dense fibrous connective tissue contains many collagen fibers packed together. This type of tissue has more specific functions than does loose connective tissue.**The types**:**denseregular connective tissue is found in tendons, which connect muscles to bones, and in ligaments, which connect bones to other bones at joints,dense irregular (is found in dermis).**

- **SPECIALIZED CONNECTIVE TISSUES**

<u>Supportive Connective Tissue</u> :Cartilage and bone are the two main supportive connective tissues. Each provides structure, shape, protection, and movement**.** Generally cartilage is more flexible than bone, because it lacks mineralization of the matrix.

In cartilage, the cells lie in small chambers called *lacunae* (sing., lacuna), separated by a solid, yet **flexible, matrix.** This matrix is formed by **cells called *chondroblasts* and *chondrocytes.*** Because this tissue lacks a direct blood supply, it often heals slowly. The three types of cartilage are distinguished by the type of fiber found in the matrix.

Hyaline cartilage the most common type of cartilage, contains only fine collagen fibers. The **matrix has a glassy, translucent** appearance. **Hyaline cartilage is found in the nose and at the ends of the long bones and the ribs,** and it forms rings in the walls of respiratory passages. The fetal skeleton also is made of this type of cartilage. Later, the cartilaginous fetal skeleton is replaced by bone.

Elastic cartilage has more elastic fibers than hyaline cartilage does. For this reason, it is more flexible and is found, for example, in the framework of the outer ear.

Fibrocartilage has a matrix containing strong collagen fibers. Fibrocartilage is found in structures that withstand tension and pressure,such as the **disks between the vertebrae in the backbone** and the cushions **in the knee joint**.

Bone is the most rigid connective tissue. It consists of an extremely **hard matrix of inorganic salts**, notably **calcium salts**. These salts are deposited around protein fibers, especially collagen fibers. The inorganic salts give bone rigidity. The protein fibers provide elasticity and strength .**Cells called *osteoblasts* and *osteoclasts***are responsible for forming the matrix in bone tissue.

Compact bone makes up the shaft of a long bone. It consists of cylindrical structural units called *osteons* .The central canal of each osteon is surrounded by rings of hard matrix**.** Bone cells(osteocyte) are located in lacunae between the rings of matrix.In the central canal, nerve fibers carry nerve impulses, and blood vessels carry nutrients that allow bone to renew itself.Thin extensions of bone cells within canaliculi (minute canals) connect the cells to each other and to the central canal.

The ends of the long bones are composed of **spongy bone** covered by compact bone. Spongy bone also surrounds the bone marrow cavity. This, in turn, is covered by compact bone, forming a "sandwich" structure. Spongy bone appears as an open, bony latticework with numerous bony bars and plates, separated by irregular spaces. Although lighter than compact bone, spongy bone is still designed for strength.

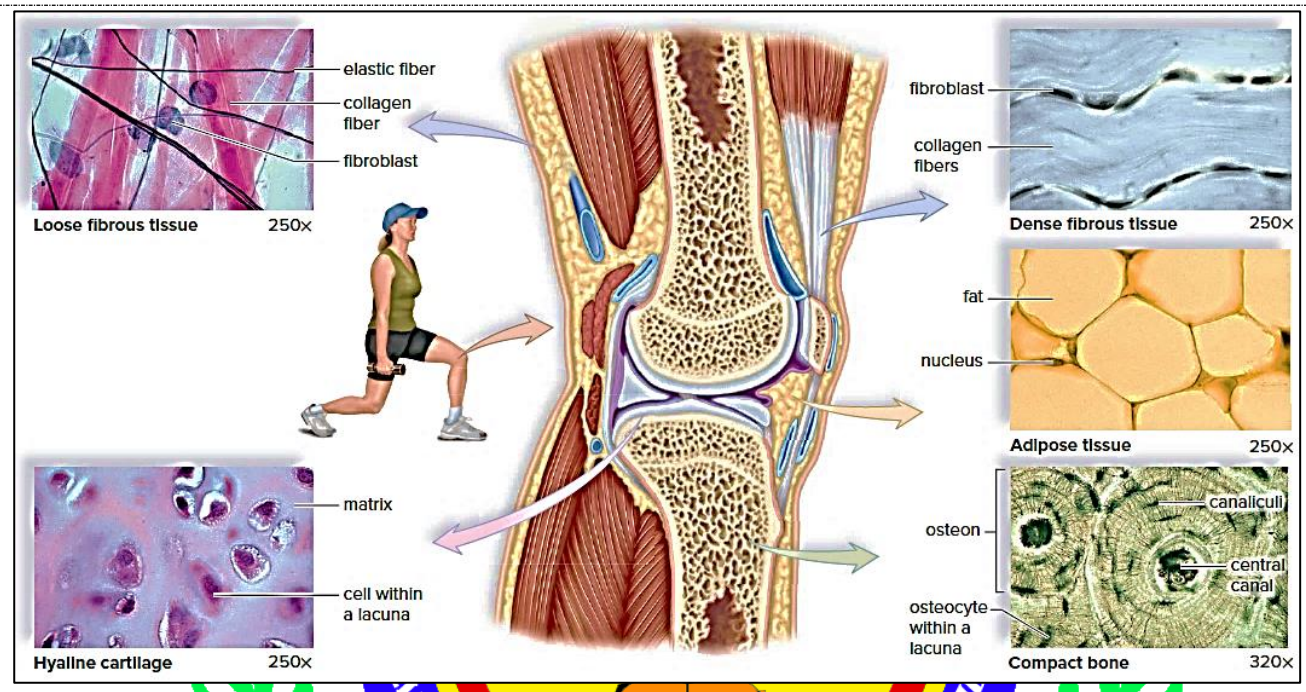

Figure : Connective tissues in the knee. Most types of connective tissue may be found in the knee.

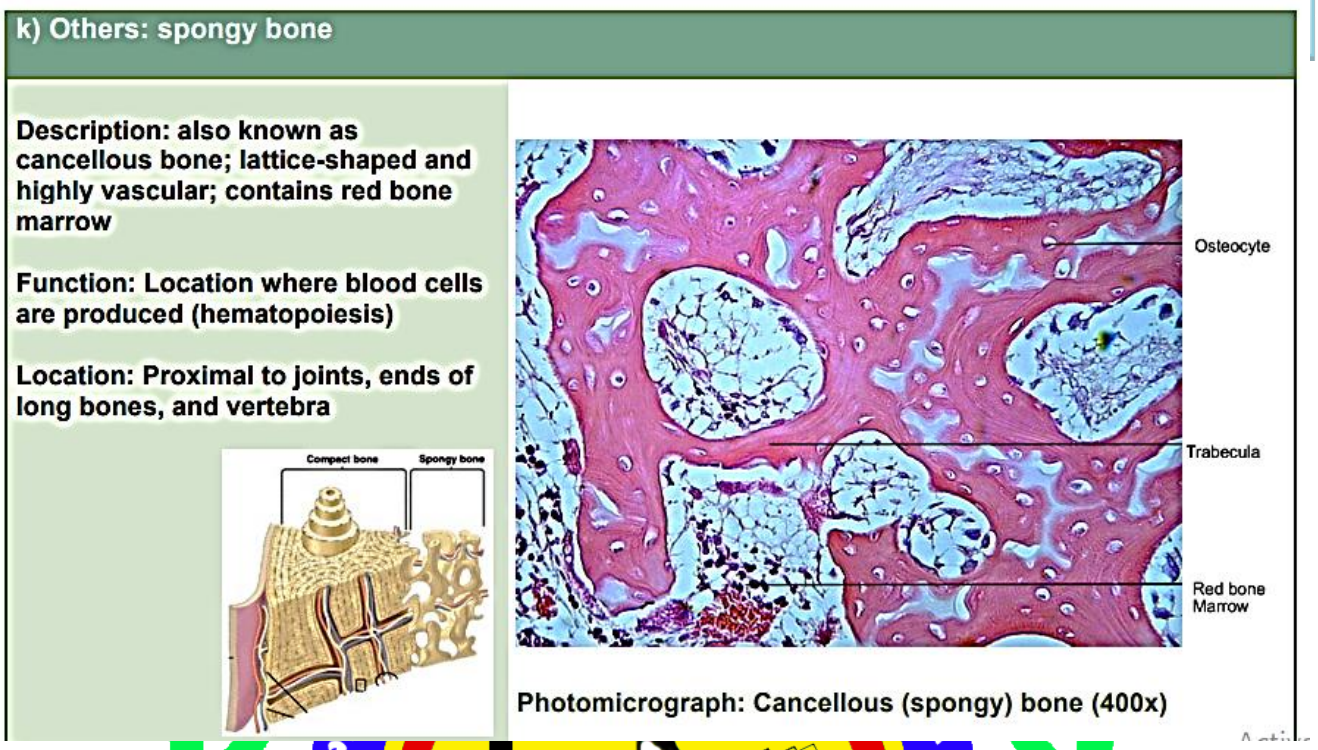

❖ HEMATOPOIETIC TISSUE (BLOOD AND BONE MARROW)

Fluid Connective Tissue

Blood is a fluid connective tissue.Blood, which consists of **formed elements and plasma**, is located in blood vessels. Blood transports nutrients and oxygen to interstitial fluid, also called extracellular fluid.

Each formed element of blood has a specific function. The **red blood cells (erythrocytes) are small, biconcave, disk-shaped cells without nuclei. The presence of the red pigment hemoglobin,** red blood cells transport oxygen.

White blood cells (leukocytes) may be distinguished from red blood cells because they have a nucleus. There are many different types of white blood cells, butall **are involved in protecting the body from infection.**

Platelets (thrombocytes) are not complete cells. Rather, **they are fragments of giant cells present only in bone marrow**. When a blood vessel is damaged, platelets form a plug that seals the vessel, and injured tissues release molecules **that help the clotting process.**

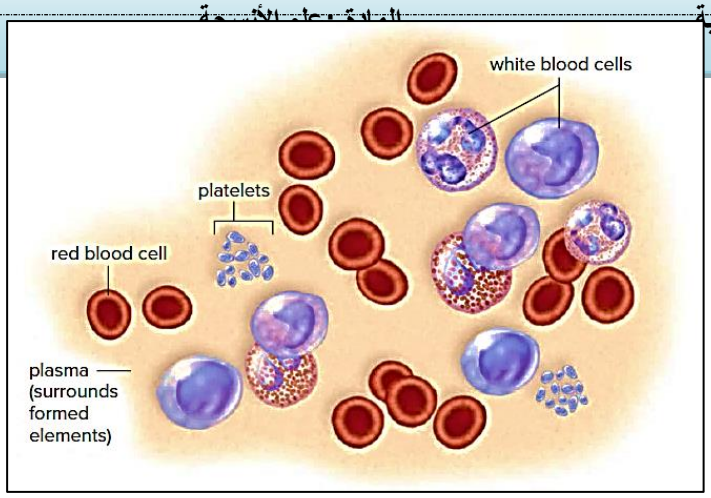

Figure : The formed elements of blood. Red blood cells, which lack a nucleus, transport oxygen.

Each type of white blood cell has a particular way to fight infections. Platelets, fragments of a particular cell, help seal injured blood vessels.

Lymph is also a fluid connective tissue. It is a clear(sometimes faintly yellow) fluid derived from the fluids surrounding the tissues. It contains white blood cells. **Lymphatic vessels absorb excess interstitial fluid** and various dissolved solutes **in the tissues. Theytransport lymph to particular vessels of the cardiovascular system. Lymph nodes, composed of fibrous connective tissue, occur alongthe length of lymphatic vessels.** Lymph nodes enlarge when you have an infection.

❖ **Lecture 6:Muscular Tissue , Moves the Body**

Muscular tissue is specialized to contract. It is composed of cells called *muscle fibers,* which contain actin and myosin filaments. The interaction of these filaments accounts for movement. **The three types of vertebrate muscular tissue are skeletal, smooth, and cardiac.**

Skeletal muscle is also called *voluntary muscle* .It is attached by tendons to the bones of the skeleton.Contraction of skeletal muscle is under **voluntary control** and occurs faster than in the other muscle types. Skeletal muscle fibers are **cylindrical and long** with **multiple nuclei**. The nuclei are **located at the periphery of the cell**, just inside the plasma membrane. The fibers have alternating light and dark bands that give them a **striated,** or striped, appearance. These bands are due to the placement of actin filaments and myosin filaments in the cell.

Smooth muscle is so named because the **cellslack striations** . Each **spindle-shaped cellhas a single nucleus.involuntary, meaning that it is not under control. is found in the walls of viscera** (intestine, bladder, and other internal organs) and blood vessels**.** it is sometimes referred to as *visceral muscle*.contracts more slowly than skeletal muscle but can remain contracted for a longer time.

Cardiac muscle is found only in the walls of the heart.it has striations, but the contraction of the heart **is involuntary,have a single, centrally placed nucleus. The cells are branched and fused together.cells are separate, but they are bound end to end at *intercalated disks*.**

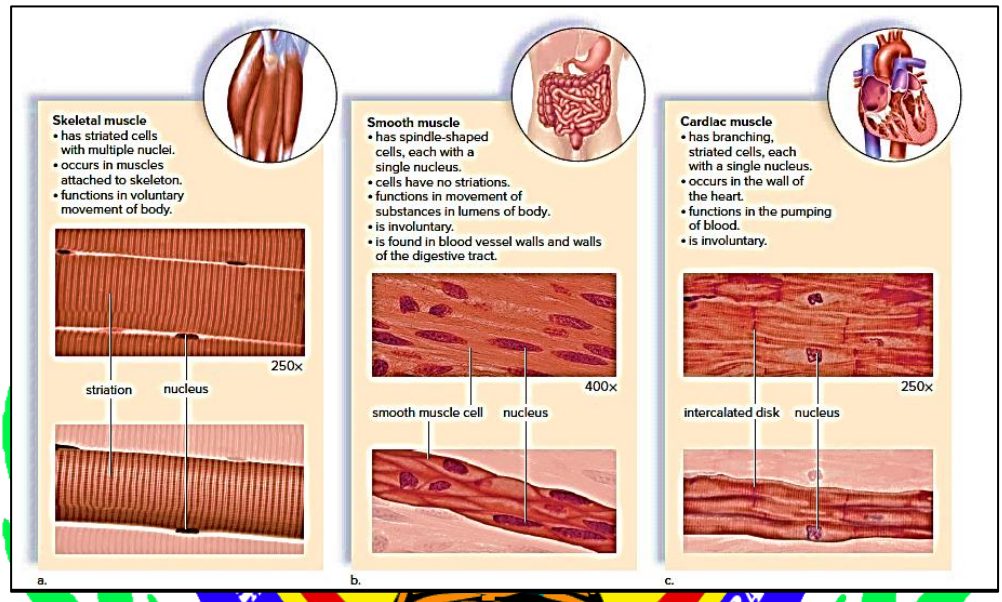

- **Muscle terminology**
- **myofiber or myocyte: a muscle cell**
- **sarcolemma: the plasma membrane of a muscle cell**
- **sarcoplasm: the cytoplasm of the muscle cell**
- **sarcoplasmic reticulum: the endoplasmic reticulum of a muscle cell**
- **sarcosome: the mitochondria of a muscle cell**
- **sarcomere: the contractile or functional unit of muscle**

- **Skeletal muscle refers tomultiple bundles of cells joined together called muscle fibers .**
- **Most are attached by <u>tendons</u> to bones.**
- Endomysium – **around single muscle fiber**
- Perimysium – around (bundle) of fibers
- Epimysium - **covers the entire skeletal muscle**
-

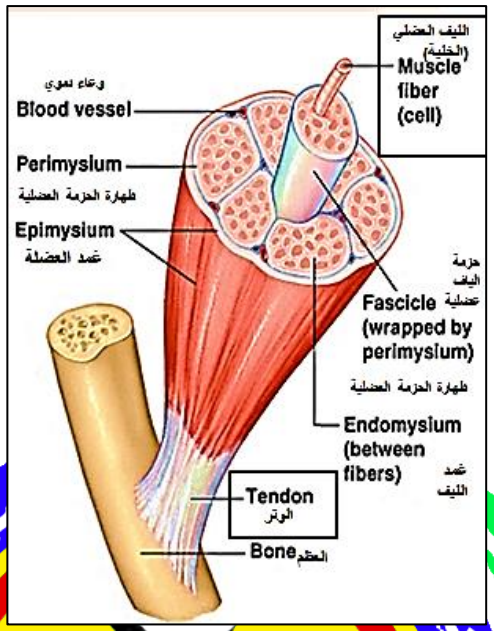

❖ Lecture 7: Nervous Tissue Communicates

Nervous tissue consists of nerve cells, called neurons, and neuroglia, the cells that support and nourish the neurons.Nervous tissue is the central component of the nervous system which serves three primary functions in the body: sensory input, integration of data, and motor output.

A neuron is a specialized cell that has three parts: dendrites, a cell body, and an axon .

A dendrite is an extension that receives signals from sensory receptors or other neurons. The cell body contains most of the cell's cytoplasm and the nucleus. An axon is an extension that conducts nerve impulses. Long axons arecovered by myelin, a white, fatty substance.

Neurons conduct nerve impulses. Neuroglia support and service neurons.Microglia are a type of neuroglia that become mobile in response to inflammation and phagocytize debris. Astrocytes lie between neurons and a capillary. Therefore, substances entering neurons from the blood must first pass through astrocytes. Oligodendrocytes form the myelin sheaths around fibers in the brain and spinal cord.

The Nervous Systemis divided into Two Main Divisions:

Peripheral Nervous Systemconsists of:-

- **Cranial nerves**

12 pair

Attached to undersurface of brain

- **Spinal nerves**

31 pair

Attached to spinal cord

Central Nervous System The human central nervous system consists of the **brain and the spinal cord.**

• **Brain**

Cerebrum: Cortical gray matter and medullary white matter. The principal and most anterior part of the brain in vertebrates, located in the front area of the skull and consisting of two hemispheres, left and right, separated by a fissure.Composed of folds called gyri.

Cerebelluma composed of many folds called folia. these folds have cortical gray matter, medullary white matter. The part of the brain at the back of the skull in vertebrates. Its function is to coordinate and regulate muscular activity.

Medullaoblongata: is a long stem-like structure which makes up the lower part ofthe brainstem.

The spinal cord is a long, thin tubular structure made up of nervous tissue, which extends from the medulla oblongata in the brainstem to the lumbar region of the vertebral column. It encloses the central canal of the spinal cord, which contains cerebrospinal fluid.Cerebrospinal fluid (CSF) is a clear, colorless body fluid found within the tissue that surrounds the brain and spinal cord.

Three types of Neurons:-

- **Sensory neurons –** bring messages to CNS.
- **Motor neurons -** carry messages from CNS **.**
- **Interneurons –** between sensory & motor neurons in the CNS.

Parts of a Neuron

Dendrite – receive stimulus and carries it impulsestoward the cell body.

Cell Body with nucleus – nucleus & most of cytoplasm**.**

Axon – fiber which carries impulses away from cell body.

Schwann Cells-Schwann cells surround all axons of neurons in the PNS creating a neurilemma around them. Neurilemma allows for potential regeneration of damaged axons**.**

Myelin sheath :lipid-rich, segmented covering on an axon.The presence of myelin speeds up the transmission of action potentials along the axon.

Node of Ranvier:a gap in the myelin sheath of a nerve, between adjacent Schwann cells.

Myelin will get laid down in segments (internodes) along the axon, leaving unmyelinated gaps known as "nodes of Ranvier**.**

Regions of the nervous system containing groupings of myelinated axons make up the "**white matter**"

Gray matteris mainly comprised of groups of neuron cell bodies, dendrites & synapses (connections between neurons)

Meninges :the brain and the spinal cord are surrounded by meninges, which have protective functions. There are the dura, arachnoid and pia maters.

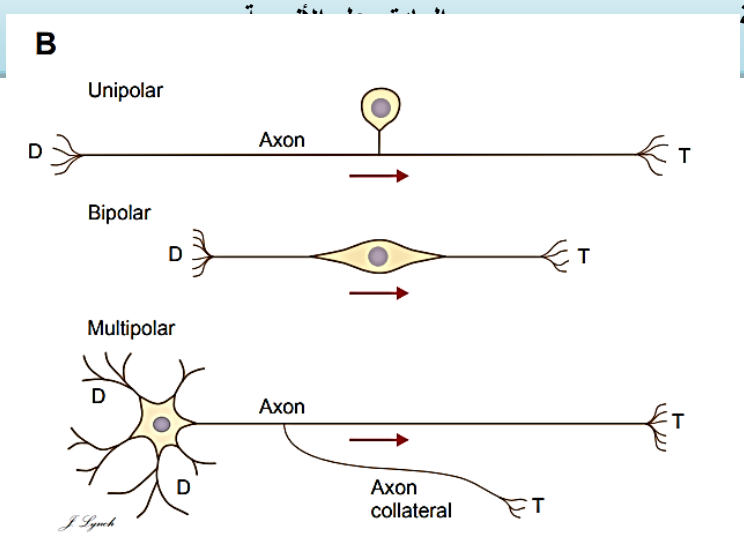

Neurons can be classified on the basis of the shapes of their cell bodies and the general arrangement of their axons and dendrites. Unipolar neurons have a single process attached to a round cell body. This process typically divides and forms a long axon extending from sensory receptors in the various tissues of the body to synaptic terminals in the CNS. Bipolar neurons have a process extending from each end of the cell body. This type of neuron is found primarily in the eye, ear, vestibular end organs, and olfactory system. Multipolar neurons have many dendrites extending from the cell body and a single axon (although the axon may split into two or more collateral axons after it leaves the cell body). Multipolar neurons are the most numerous in the nervous system and have many different shapes and sizes. (D, dendrites; T, axon terminals.

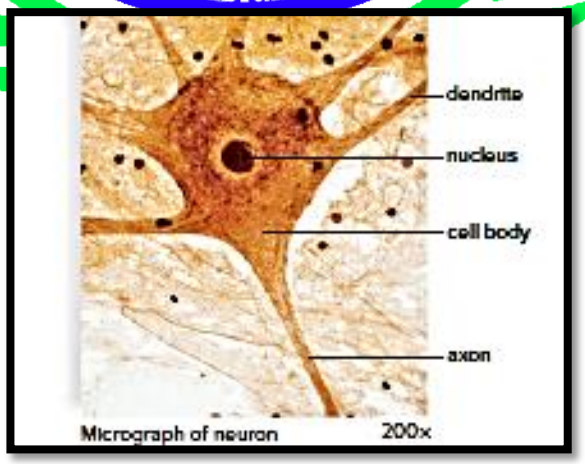

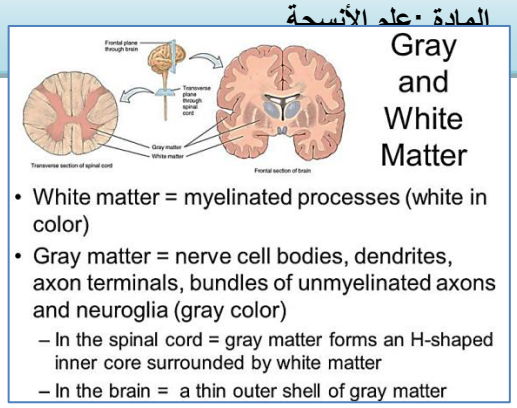

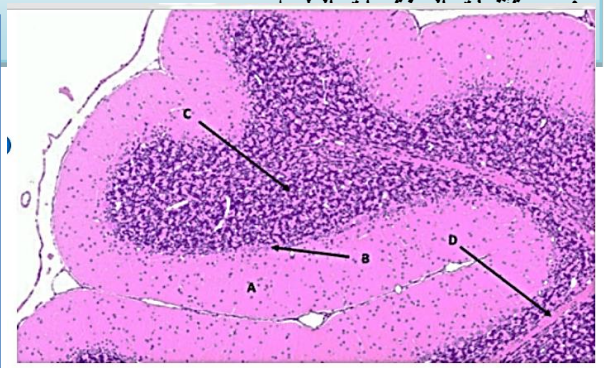

1.2 Histology of human brain tissue. In pink the grey matter (A) and in violet the white matter (C).

- **Lecture8&9&10 :Integumentary System**

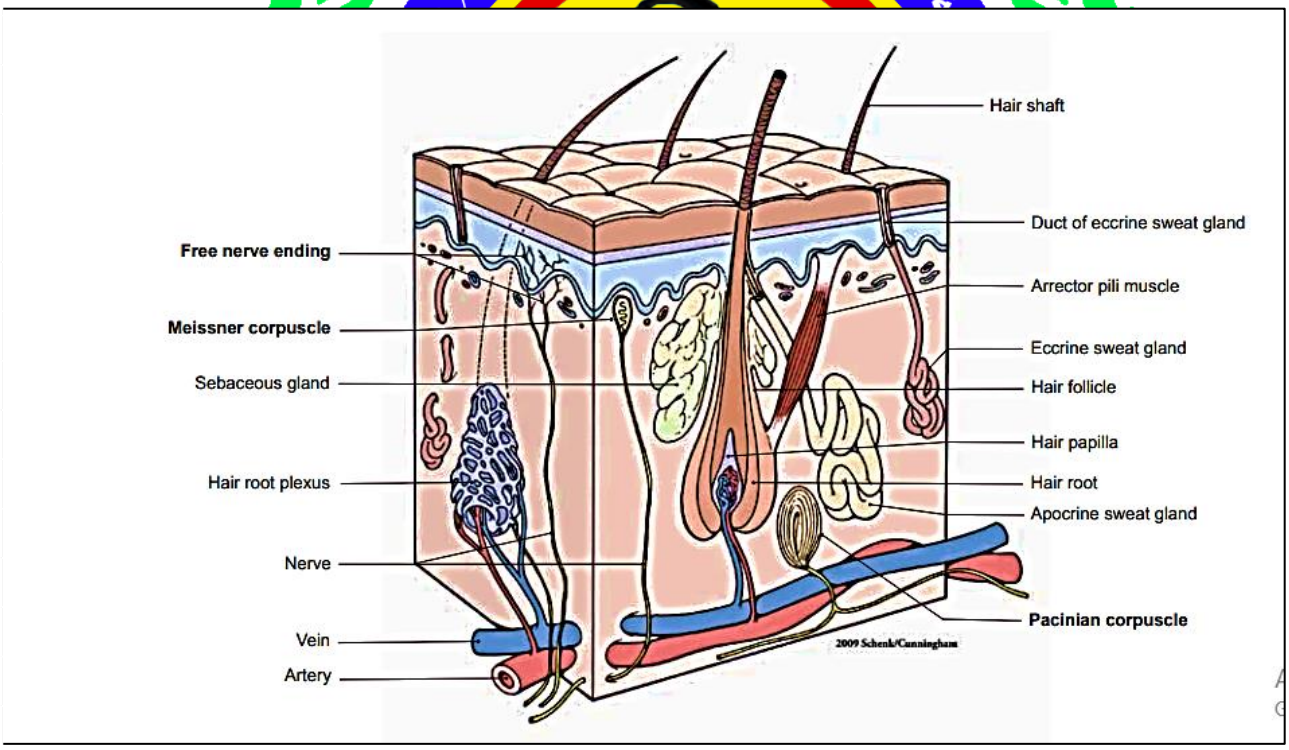

Figure 1: The structure of the skin

The skin is composed of epithelium, connective tissue , muscles, nerves, blood vessels, and associated structures (glands , hair follicles , and nails). It can be **divided into two basic layers: epidermis and dermis** . The epidermis is the superficial layer of the skinIt consists of a stratified squamous epithelium. The dermis is a layer of connective tissue beneath the epidermis . There is a

transition layer between the skin and underlying muscle called the hypodermis (subcutaneous layer), which, strictly speaking, is not a component of the skin but is closely associated with the skin This layer contains loose connective tissue, adipose tissue, nerves, arteries, and veins. The skin contains several sensory structures, which respond to somatosensory stimuli. These include free nerve endings (pain or temperature), Merkel disks (continuous touch), and Meissner corpuscles (touch). Pacinian corpuscles (vibration) can be found in the subcutaneous layer (hypodermis). There are several types of glands in the skin, including sebaceous glands, eccrine sweat glands, and apocrine sweat glands.

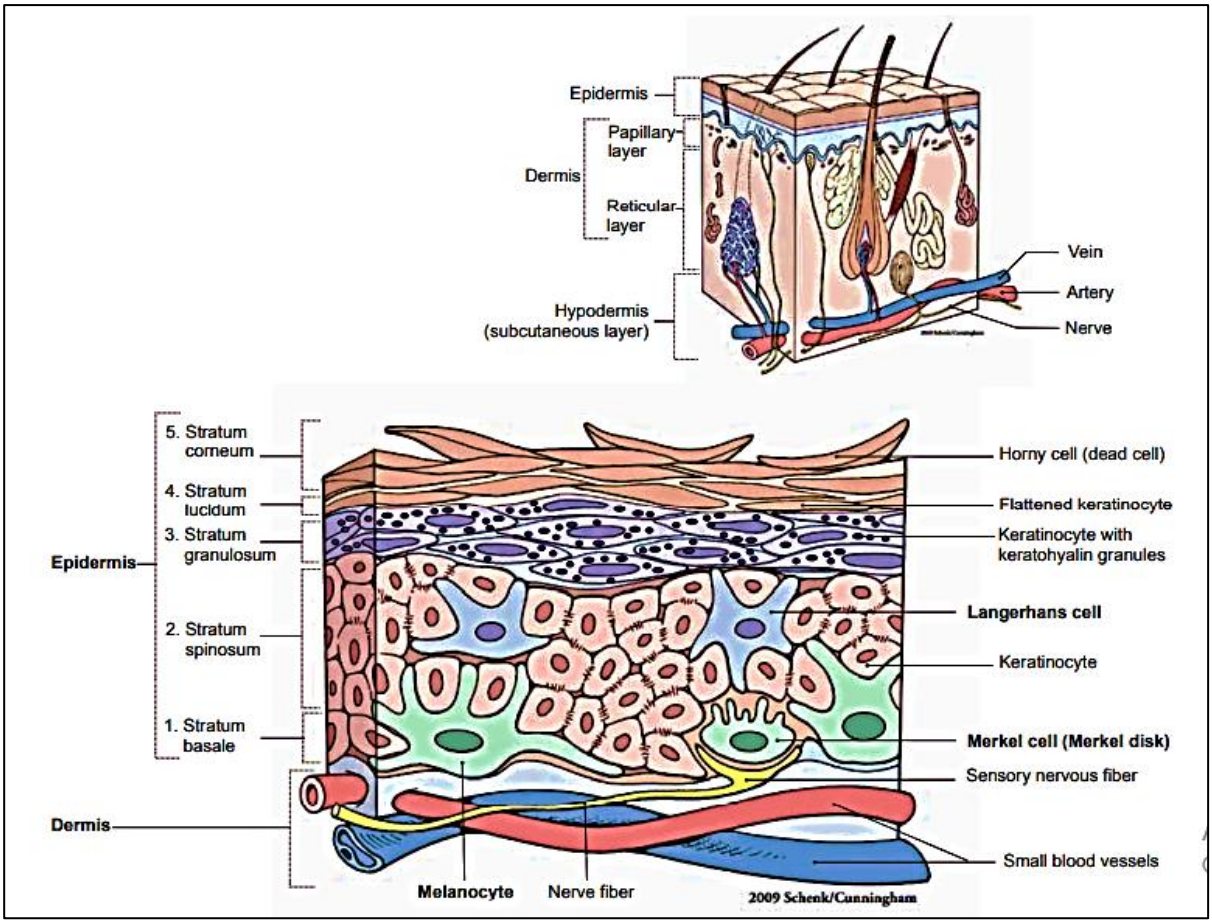

Figure 2:the layers of the epidermis.

The epidermis is composed of five cell layers. **(1)The stratum basale is composed of a single layer of cuboidal** or tall cuboidal cells, **melanocytes and Merkel** cells which are also called Merkel cell neurite complexes or Merkel disks. Many of these cells are actually stem cells; they divide continuously

and migrate from the basal layer toward the surface and give rise to keratinocytes in the other layers. **(2) The stratum spinosum** contains polygon-shaped keratinocytes These cells are interconnected with each other by desmosomes. Langerhans cells are often found in this layer. The stratum basale and the stratum

spinosum are the only layers with mitotically active cellsالخلايا النشطة الانقسامية, and, together they are also called the Malpighian layer. **(3) The stratum granulosum contains three to five layers of keratinocytes with flattened nuclei.** The cytoplasm of the cells is filled with basophilic keratohyalin granules from which the name derives. The cytoplasm also contains lamellar granules, which can release their contents into the intercellular spaces to help seal the skin, preventing water loss. This layer is more obvious in thick skin; only a single cell layer is visible in thin skin. **(4) The stratum lucidum** is a very thin, clear layer that contains keratinocytes with pycnotic nuclei. This layer is found only in thick skin. pycnotic. .**(5) The stratum corneum** is the top layer of the epidermis. It contains many layers of flattened cells filled with mature keratin. These are dead cells with no nuclei or organelles. The cells in this layer, which are constantly replaced by cells from deeper layers, form a barrier to prevent loss of water and entry of pathogens. This layer is much thicker in thick skin than in thin skin. ‹

Structures of the Skin

I. Layers of the skin

- A. Epidermis
  - 1. Stratum corneum
  - 2. Stratum lucidum
  - 3. Stratum granulosum
  - 4. Stratum spinosum
  - 5. Stratum basale
- B. Dermis
  - 1. Papillary layer
    - a. Free nerve endings
    - b. Meissner corpuscles
  - 2. Reticular layer
- C. Hypodermis (subcutaneous layer)
  - 1. Loose connective tissue
  - 2. Adipose tissue
  - 3. Pacinian corpuscles
  - 4. Arteries and veins
  - 5. Nerves

II. Accessory structures

- A. Glands
  - 1. Sebaceous glands
  - 2. Eccrine sweat glands
  - 3. Apocrine sweat glands
- B. Hair
  - 1. Hair shaft
  - 2. Hair follicles
- C. Nail
  - 1. Nail bed
  - 2. Nail matrix
  - 3. Eponychium
  - 4. Hyponychium
- D. Sensory receptors
  - 1. Meissner corpuscles
  - 2. Free nerve endings
  - 3. Pacinian corpuscles
  - 4. Merkel cells (Merkel cell neurite complexes or Merkel disks)

eccrine sweat gland: relating to or denoting multicellular glands that do not lose cytoplasm in their secretions, especially the sweat glands found widely distributed on the skin.

Apocrinesweat gland: relating to or denoting multicellular glands which release some of their cytoplasm in their secretions, especially the sweat glands associated with hair follicles in the armpits and pubic regions.

Integumentary System

Thick Skin

The skin can be classified into thick skin and thin skin based on the thickness of the epidermis. Thick skin has a thick epidermis (400–600 µm) with five distinct cell layers. The stratum corneum is extremely thick in this skin. Thick skin covers the palms of the hands and soles of the feet. Thick skin has abundant eccrine sweat glands and lacks hair follicles. The epidermis is a stratified squamous epithelium. Because it is an avascular tissue (no direct blood supply), nutrients are delivered to the tissue by fluid diffusion from the dermis (connective tissue). The dermis is composed of a superficial papillary layer, a layer of loose connective tissue, and a deeper reticular layer, which is a thick layer of dense irregular connective tissue.

Figure 1.Thick skin, palm. H&E

Layers of the epidermis, palm

The epidermis of thick skin has five layers. **(1) The stratum basale** contains a single layer of cuboidal/tall cuboidal cells (stem cells) and sits upon the basement membrane. This layer forms a dividing line between the epidermis and dermis (dotted line). **(2) The stratum spinosum** contains 5 to 10 layers of polyhedral keratinocytes, flattened toward the surface. These cells are also called prickle cells. **(3) The stratum granulosum** contains three to five layers of flattened keratinocytes filled with keratohyaline granules, which appear dark blue here. **(4) The stratum lucidum** is a very thin layer containing extremely flattened and tightly packed keratinocytes filled with keratin filaments. Their nuclei are beginning to be eliminated. **(5) The stratum corneum** is a layer of dead, nonnucleated cells, which form the most superficial layer of the skin. Cells in this layer are constantly sloughed off and replaced by new cells.

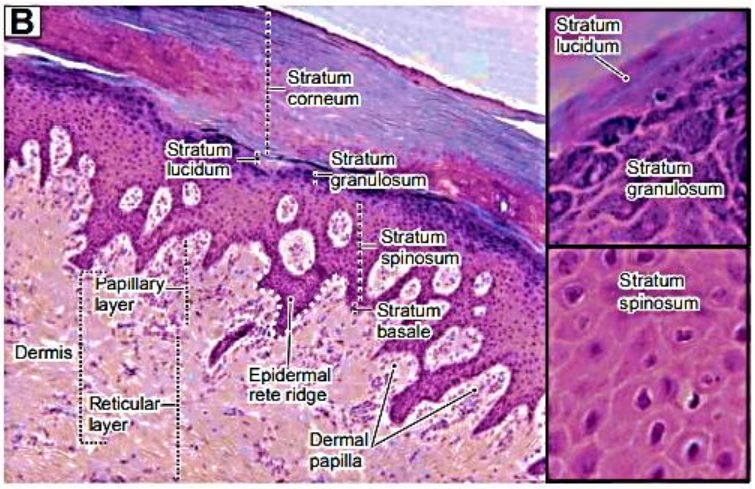

Figure 2. Layers of the epidermis, palm. H&E

Dermal papilla, palm.

The border between the epidermis and dermis (dotted white line) is expanded into folds. The dermis is a connective tissue layer, which contains blood vessels, nerves, and sensory receptors (free nerve endings and Meissner corpuscles). The portion of the epidermis that projects into the dermis is termed the epidermal rete ridge, and the portion of the dermis that projects into the epidermis is called the dermal papilla. This unique feature increases the contact area between these two layers, preventing the epidermis from detaching from the dermis. The dermal papilla contains loose connective tissue that includes many capillaries, free nerve endings, and encapsulated sensory receptors. Meissner corpuscles are shown here. The nerve fibers cannot be seen in H&E stains; demonstration of nerve fibers requires special stains . Meissner corpuscles are responsible for discriminative touch and are more numerous in thick skin such as at the tips of the fingers. These receptors help us to distinguish between, for example, different coins by touch alone.

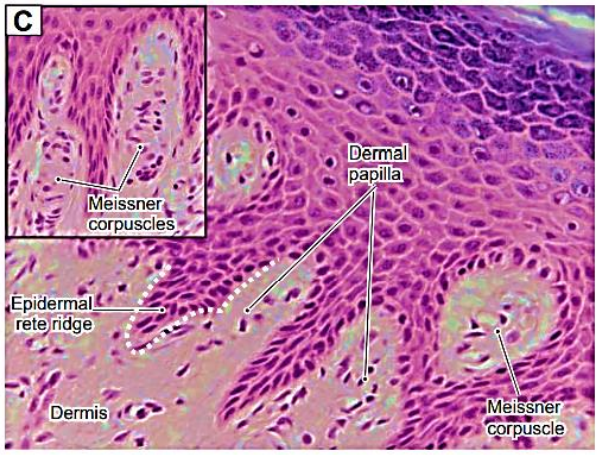

Figure 3.Dermal papilla, palm. H&E

Thin skin

Thin skin covers the entire body surface except for the palms of the hands and the soles of the feet. Thin skin has a thin epidermis, largely because its stratum corneum is much reduced compared to that of thick skin. In contrast to thick skin, thin skin contains hair follicles and their associated sebaceous glands. This section shows the epidermis and dermis of the skin and a deeper layer of subcutaneous tissue called the hypodermis. The hypodermis is a layer of loose connective tissue, which contains adipose tissue, nerves, arteries, and veins. The nerves give off branches, which provide the various types of sensory and autonomic nerve endings in the dermis. Pacinian corpuscles, sensory receptors that respond to vibration stimuli, are found in the hypodermis of both thin and thick skin. They are found in many regions of the body but are more numerous in the tips of the fingers and toes than in other areas . The hypodermis serves as a transition layer, providing the dermis with a flexible attachment to the underlying muscles and other structures.

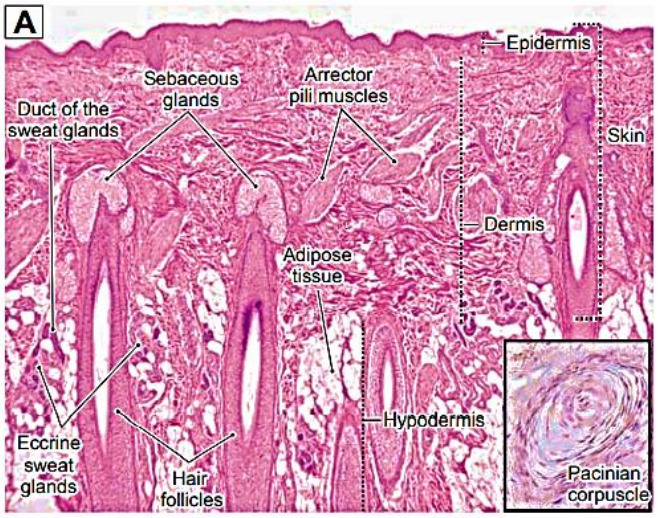

Figure 4.Thin skin, scalp. H&E

Special types of cells in the epidermis, thin skin

Keratinocytes make up the bulk of the epidermis, but there are additional cell types: melanocytes, Merkel cells, and Langerhans cells. All three types of cells have clear cytoplasm and are some times called clear cells. It is difficult to distinguish among them in H&E-stained sections. Melanocytes and Merkel cells are both located in the stratum basale where they are scattered among the basal cuboidal cells. In contrast, Langerhans cells are typically found in the stratum spinosum. The functions of the three cells are quite different: **(1) Melanocytes produce melanin granules** and insert them into keratinocytes. **(2) Merkel cells are receptor cells,** that establish synaptic contacts with sensory nerve terminals; they have cytoplasmic granules, which contain neurotransmitters .**(3) Langerhans cells are**

monocyte derivatives, which play an important role in capturing antigens and presenting them to lymphocytes, thereby participating in the cutaneous immune response.

Figure 5.Special types of cells in the epidermis, thin skin. H&E

TABLE 1. Comparison of Thick and Thin Skin

Type of Skin	Epidermis	Hair/Hair Follicles	Glands	Sensory Receptors	Location/ Distribution	Special Features
Thick skin	Five layers; thick stratum corneum; thick stratum granulosum	No	Lack of sebaceous glands; more eccrine sweat glands	More receptors	Palms of the hand and soles of the feet	*Thick epidermis:* thick stratum corneum; stratum lucidum present; several cell layers of stratum granulosum
Thin skin	Four layers; no stratum lucidum; single layer of or no stratum granulosum	Present in most areas (except a few places, such as lips, labia minora, and glans penis)	Many sebaceous glands; fewer eccrine sweat glands	Fewer receptors	Entire body except thick skin areas	*Thin epidermis:* thin stratum corneum; stratum lucidum absent; one layer or no stratum granulosum

Accessory Structures

Sebaceous glands are found in thin skin, usually associated with hair follicles. They are most numerous in the skin of the scalp and face. Sebaceous glands are **classified as simple branched acinar glands**. The **secretory cells are lipid** producing cells, arranged into several acini, which open into a short duct. Usually, the ducts of sebaceous glands empty their oily secretion, called sebum, into a hair follicle however, the ducts sometimes open directly onto the surface of the skin. Sebaceous glands release their products by holocrine secretion, that is, by the disintegration of entire cells.

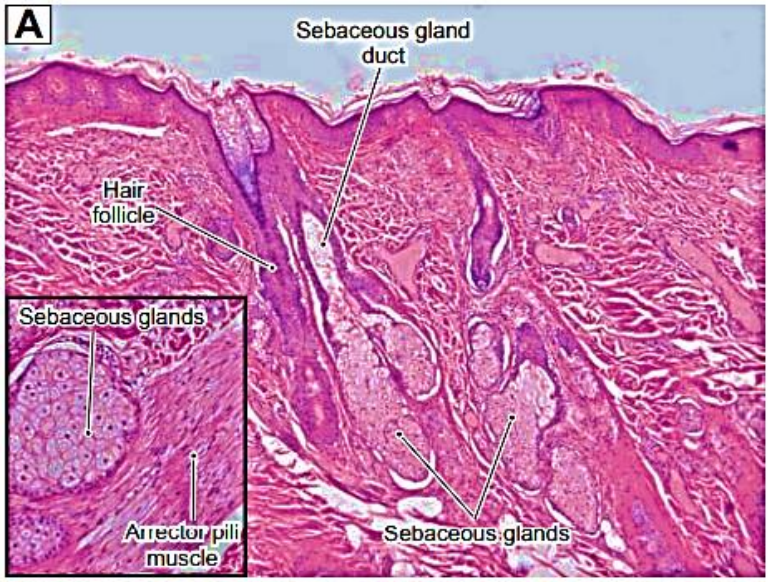

Figure 6.Sebaceous gland, thin skin (scalp). H&E

Eccrine (merocrine) sweat gland scan be found in both thin and thick skin over most of the body. They are more numerous in the palms and soles. Eccrine sweat glands produce a clear watery product called sweat. These glands are simple glands in which the secretory cells are arranged into coiled tubules. These glands have long unbranched, but coiled, ducts, which are lined by two layers of cuboidal cells and open directly onto the surface of the skin.

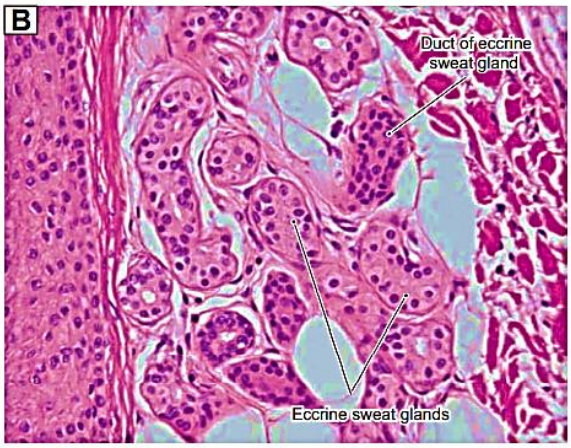

Figure 7.Eccrine sweat gland, thin skin (scalp). H&E

Apocrine sweat glands are simple coiled tubular glands like the eccrine sweat glands, but their lumens are larger (about 10 times larger than those of the eccrine sweat glands) and their ducts

empty into the superficial regions of the hair follicles. The secretory cells of the apocrine glands release their products by shedding part of their apical cytoplasm; this is called apocrine

secretion.The tubules of the glands are lined by cuboidal or columnar epithelial cells, depending on the secretory stage.

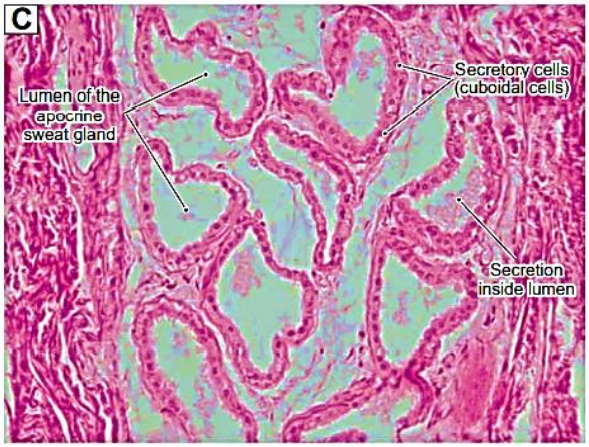

Figure 8.Apocrine sweat glands, axilla. H&E.

Hair follicle

A cross section of a hair follicle is shown on the left and a photomicrograph of a cross section of a hair follicle from the scalp on the right. The structures of the hair follicle containing a hair shaft include (from inside to outside) the hair medulla (thin core of the hair shaft), the hair cortex (keratinized cells surrounding the medulla), the hair cuticle (outermost layer of the hair shaft), the inner root sheath (cellular sheath that extends from the hair bulb and surrounds and grows along with the hair), the outer root sheath (a cellular sheath which is a continuation of the epidermis), and the connective tissue sheath (dermal root sheath).

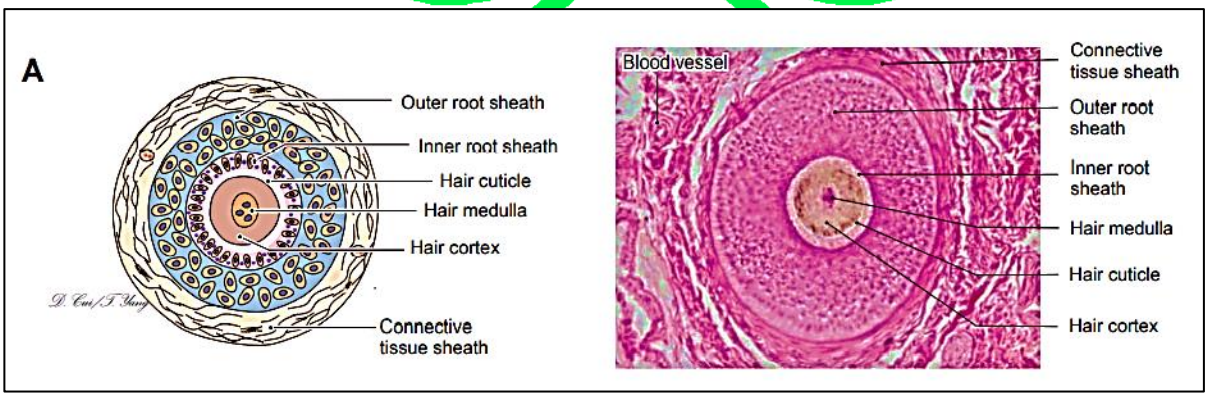

Figure 9.Hair follicle. H&E

Hair follicles, thin skin (scalp)

Hair follicles are the structures that produce the hair and maintain hair growth. They are cellular structures extending from the epidermis into the dermis or hypodermis. The basal region of the hair follicle forms a balloon-shaped structure called the hair bulb, which is composed of the hair root and the dermal papilla. The hair root contains melanocytes and a group of epithelial cells called the matrix or germinal matrix. These cells are capable of cell division and give rise to the inner root sheath and to the hair. The epithelial cells form a cap around the dermal papilla (hair papilla). The dermal papilla contains capillaries and nerve fibers that supply the hair follicle. The interaction between the hair bulb and dermal papilla induces hair follicle differentiation and the growth of the hair. The photomicrograph shows a longitudinal section of hair follicles. The inset shows melanin granules, which give color to the hair. The melanin granules are produced by melanocytes in the hair bulb.

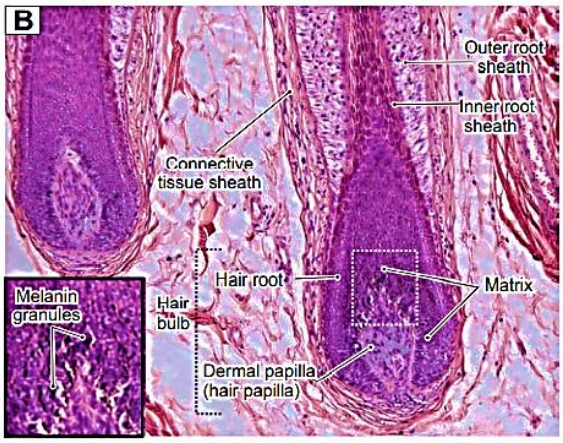

Figure 10. Hair follicles, thin skin (scalp). H&E

Reference :-

1. Pal GP(2015).Textbook of Histology 4th Edition 2015.
2. Inderbir Singh (2018).Textbook of Human Histology, 6th Edition
3. Neelam Vasudeva(2015).Inderbir Singh's Textbook of Human Histology 7th Edition .
4. Victor P.E.(2015).Atlas of histology,11th edition.
5. Dongmei Cui,(2011). Atlas of Histology with Functional and Clinical Correlations, First Edition.page:431.

6. Patrice F Spitalnik MD(2016).HISTOLOGY LABORATORY MANUAL.p:106.
7. Wolfgang Kuehnel, M.D.2003.Color Atlas of Cytology, Histology, and Microscopic Anatomy 4th edition, revised and enlarged,pages:516.
8. Robert ,L.S.2008.ATLAS OF HUMEN HISTOLOGY,pages:363.
9. Frank H.Netter,(2015). Atlas of Human Anatomy , 6th edition.640pages.
10. Drake R.L. (eds) (2019). Gray's Anatomy for Students. London: Elsevier.
11. Waugh A. and Grant A (2018). The musculoskeletal system. In: Ross & Wilson Anatomy and Physiology in Health and Illness. London: Elsevier.
12. Tortora, G.J., Derrickson, B. (2016). Principles of Anatomy and Physiology (15th ed.). J. Wiley. ISBN 978-1-119-34373-8.
13. Netter, F. (2019). Atlas of Human Anatomy (7th ed.). Philadelphia, PA: Saunders.
14. Standring, S. (2016). Gray's Anatomy (41tst ed.). Edinburgh: Elsevier Churchill Livingstone.
15. Burnand, Kevin G, and Norman S. Browse: (2015). Browse's Introduction To The Symptoms & Signs Of Surgical Disease. 5th ed., Boca Raton, FL, CRC Press, Taylor & Francis Group,.
16. Moore K.,Dalley A.(2018). Clinically Anatomy, 2nd edition.
17. James Lowe, Peter Anderson, Susan Anderson(2018). Human Histology. 5th Edition .
18. Hussain A. Sattar,2018. Fundamentals of Pathology ,MEDICAL COURSE AND STEP 1 REVIEW 2018 EDITION, 1st edition ,p:408.
19. Alexandera Burke-Smith (2008) .Human Anatomy , third edition.
20. Wick, Mark R. (2019). "The hematoxylin and eosin stain in anatomic pathology—An often-neglected focus of quality assurance in the laboratory". Seminars in Diagnostic Pathology. 36 (5): 303–311.
21. Anthony L Mescher(2018). Junqueira's Basic Histology, 16th edition.